

Assessment of Common Errors and Subjective Quality of Digital Panoramic Radiographs in a Dental Institution

Nithin Kumar

Department of Oral and Maxillofacial Surgery, Faculty of Dentistry, Tishk International University, Erbil, Iraq

Abstract

Aim: The aim of the study was to determine the incidence of patient preparation and positioning errors during panoramic radiographic imaging and to assess the subjective quality of panoramic radiographs in a sample of records collected from a dental institution. **Materials and Methods:** The study material was 1000 randomly selected panoramic radiographs obtained from the database of the department of oral and maxillofacial radiology. Patient preparation and positioning errors of the radiographs were evaluated and categorized into nine groups. The sample radiographs were also evaluated for subjective quality according to a three-point quality scale by the National Radiological Protection Board (United Kingdom) as “excellent,” “diagnostically acceptable,” or “unacceptable.” **Results:** Out of 1000 radiographs evaluated, failure to position the tongue against palate was the most common error at 69.5% and patient movement during radiographic exposure was the least common error at 0.4%. As per the subjective quality ratings, 22.4% of the radiograph had excellent quality, 66.4% were diagnostically acceptable, and 13.2% were unacceptable. **Conclusion:** The incidence of patient positioning errors in the panoramic radiographs was relatively common. The quality of the diagnostic panoramic radiographs could be improved by better operator education and awareness in relation to patient preparation and positioning.

Keywords: Panoramic radiograph, patient preparation, positioning errors, radiographic quality

Submitted: 12-Sep-2019; **Revised:** 01-Apr-2020; **Accepted:** 19-Apr-2020; **Published:** 28-May-2020

INTRODUCTION

Panoramic radiograph is a valuable tool used in the field of dentistry for the diagnosis and treatment planning of various oral and dental problems. However, various studies have shown that a considerable number of these panoramic radiographs obtained are of marginal or nondiagnostic quality.^[1-3] Low-quality radiographs can lead to misinterpretation, resulting in incorrect diagnosis and treatment planning.^[4] As a result, these radiographs have to be repeated for no inherent limitation of the equipment but rather the result of lack of operator skill and errors made during patient preparation and positioning. As the use of digital processing techniques has minimized the processing errors, special attention must be given on operator training on patient preparation and positioning for a good-quality radiographic image.^[5] Good-quality dental panoramic radiograph not only prevents any misinterpretation causing incorrect diagnosis and treatment planning but also maximizes the benefits to the patient by minimizing the radiation exposure and the financial cost.^[6] Radiation exposure due to

the repetition of panoramic radiograph has been associated with an increased risk of inducing cancer.^[7,8] For this reason, it is imperative to periodically assess the quality of panoramic radiographs and to evaluate common errors relating to patient preparation and positioning in order to prevent developing faulty panoramic radiograph and the subsequent complications associated with it. When the literature was review, no such study has been done in Iraq to assess common patient positioning and preparation errors on dental panoramic radiographs.

MATERIALS AND METHODS

For this study, pretreatment digital panoramic radiographs of 1000 patients were randomly selected from the

Address for correspondence: Dr. Nithin Kumar,
Laxmi Nilaya, Near Anganawadi, Guddayangadi, Panjimogeru Post,
Mangalore - 575 013, Karnataka, India.
E-mail: drnithinkumar1984@gmail.com

Access this article online

Quick Response Code:



Website:
www.dmrjournal.org

DOI:
10.4103/dmr.dmr_22_19

This is an open access journal, and articles are distributed under the terms of the Creative Commons Attribution-NonCommercial-ShareAlike 4.0 License, which allows others to remix, tweak, and build upon the work non-commercially, as long as appropriate credit is given and the new creations are licensed under the identical terms.

For reprints contact: reprints@medknow.com

How to cite this article: Kumar N. Assessment of common errors and subjective quality of digital panoramic radiographs in a dental institution. *Dent Med Res* 2020;8:23-6.

database of the department of oral and maxillofacial radiology, taken between September 2018 and June 2019. All projections were made with the same radiographic equipment (NewTom Giano, CEFLA s.c., Imola, Italy), according to the manufacturer’s instructions and processed digitally. Radiographs were evaluated by a single examiner, and the frequency of errors was recorded according to the criteria summarized in Table 1. A three-point quality scale by the National Radiological Protection Board was also used by the examiner to rate the quality of each radiograph [Table 2]. Intraexaminer reliability was tested by re-examining random panoramic radiographic images a month after initial assessment to ensure the consistency of radiographic evaluation. The results were presented using descriptive statistics. Data tabulation and analysis was done using the Statistical Package for the Social Sciences 25 software (SPSS Inc., Chicago, IL, USA).

RESULTS

Out of the total 1000 randomly selected panoramic radiographs, 224 (22.4.0%) radiographs had no errors, whereas 776 (77.6%) radiographs showed one or more patient preparation and positioning errors. The most common preparation and positioning errors observed in the radiographs were failure to position the tongue against the palate (69.5%). The least common error observed was patient movement during exposure (0.4%). Figure 1 shows the frequency distribution of common errors observed in the sample studied.

Only 224 radiographs showed no errors in preparation and positioning during exposure, and hence, they were classified as excellent quality radiographs based on the subjective quality rating system.^[7] Six hundred and sixty-four radiographs were diagnostically acceptable quality as the errors did not detract from the diagnostic utility of the radiograph. The remaining 132 radiographs were diagnostically unacceptable as they affected the diagnostic interpretation of the radiograph [Figure 2].

DISCUSSION

Panoramic dental radiographs have long been one of the most common modalities of radiographic investigation for imaging dental structures among dentists due to their many advantages.^[9,10] It provides a wider field of view of both dental arches and large number of anatomical structures such as the maxillary sinuses, the temporomandibular joint, and the hyoid bone.^[11,12]

Radiographic errors are a common occurrence when relating to panoramic dental radiography. This can be due to processing errors or relating to patient preparation and positioning errors. However, since the incidence of processing errors has largely been minimized by the use of digital processing techniques, the operator must pay special attention on patient preparation and positioning for a panoramic radiograph free from these errors. Errors in radiographic image result in reduced diagnostic benefits requiring repeated patient exposure to unnecessary ionizing radiations when the radiographic investigation is

Table 1: Summary of common preparation and positioning errors in dental panoramic radiograph

Errors	Criteria
Patient preparation error	
Patient wearing earrings, hairpin, jewelry, or prosthetic or orthodontic appliances	Appearance of artifact shadow of the offending object on radiograph
Patient positioning error	
Patient positioned far backward	Upper and lower anterior teeth appear magnified and out of focus
Patient positioned too forward	Upper and lower anterior teeth appear narrow and fuzzy Spine superimposed on the ramus area Premolars severely overlapped
Patient’s chin raised too high	Flat or reverse occlusal plane The mandible is broad and flat Increased intercondylar distance Magnified and out of focus anterior teeth
Patient’s chin tipped too low	Excessive curvature of the occlusal plane (smile line) The mandible is V shaped Decreased intercondylar distance Narrow and out of focus anterior teeth
Patient movement during radiation exposure	Blurring and distortion of the part of the image produced at the time of the movement
The neck of the patient not in an erect position	Ghost image of the cervical vertebra producing white opacity in the anterior region
Failure to position the tongue against the palate	Radiolucency between the palate and the dorsum of the tongue Root apices of the maxillary teeth are obscured
The head of the patient twisted/ rotated	Structures away from the film are magnified and closest to the film are minified Posterior teeth are wide on one side and narrow on the other Height and width of condyles are not normal

Table 2: Subjective quality rating of radiographs by national radiological protection board

Rating	Quality	Basis
1	Excellent	No errors of patient preparation, exposure, positioning, processing, or film handling
2	Diagnostically acceptable	Some errors of patient preparation, exposure, positioning, processing, or film handling, but which do not detract from the diagnostic utility of the radiograph
3	Unacceptable	Errors of patient preparation, exposure, positioning, processing, or film handling, which render the radiograph diagnostically unacceptable

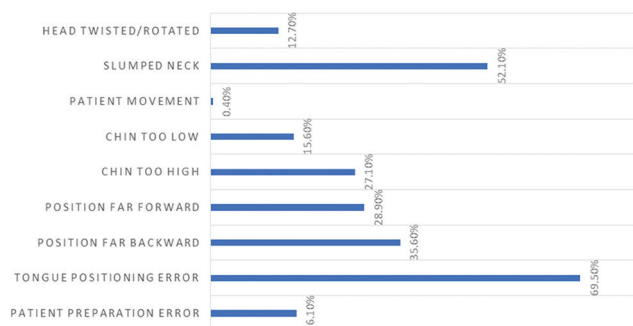


Figure 1: Frequency of distribution of common patient preparation and positioning errors observed in the studied sample

repeated.^[5,6] Hence, it becomes of utmost importance that we study the incidence of the various patient preparation and positioning errors that can occur in panoramic dental radiography. This can help in better training of the operators to prevent such errors from occurring. However, despite all the efforts, some errors are inevitable due to patient factors such as physical status and inability to comply with the instructions while taking radiograph. Dental professionals, while interpreting these radiographs, must be aware of all these inevitable errors and account for the changes to the best of their experience and clinical expertise.^[6]

In the present study, 77.6% of the panoramic radiographs had one or more radiographic errors relating to patient preparation and position. This can be comparable to the studies done by Dhillon *et al.* and Khan *et al.* where the incidence of radiographic errors was 89% and 79%, respectively.^[5,6] Failure to position the tongue against the palate during the radiographic exposure remains the most common positioning error with incidence of 69.5% in this study. This continues to be an issue as pointed out by other studies as to the lack of patient understanding of the tongue position during panoramic radiography.^[5,6,13-15] This may be attributed to the inability of the operator to properly communicate the importance of the tongue position to the patient or may be a result of patient's inability to follow the operator's instruction. Hence, it might be better for the operator to physically demonstrate to the patient the proper positioning of the tongue before radiographic exposure.

The neck of the patient not being erect was the second most common patient positioning error at 52.1%, which was significantly higher than other studies.^[5,6] This may be related to the ergonomics of the radiographic equipment which may

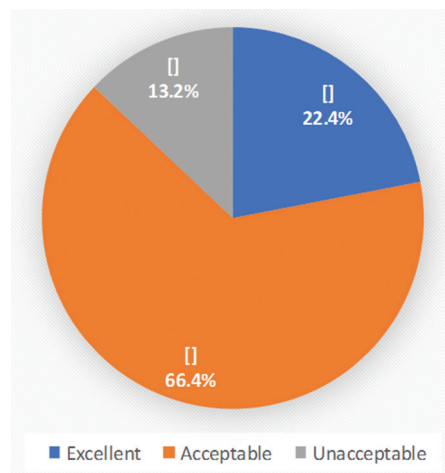


Figure 2: Subjective quality rating of radiographs in the studied sample

be causing the patient to have a natural tendency to slump down his neck while holding the handles of the machine. To avoid this error, before taking a radiograph, the operator should make sure that the patient's neck is extended with erect back and spine.

In this study, backward positioning error (35.6%) seemed to be more prevalent than forward positioning (28.9%). Other studies also had showed that backward positioning error was more common when compared to the forward positioning of the patient, but the incidence of these errors seems to be lower as compared to the present study.^[5,6,13] In relation to the chin position, more errors were seen with the patient's chin raised too high (27.1%) than the chin being tipped low (15.6%). This can be an overcompensation that patients tend to do when instructed to stay upright during radiographic exposure. Hence, the operator should also observe the chin position when the patient is told to keep the neck extended with erect back and spine. In many instances, multiple errors occurred in one image; this could be due to spending inadequate time for patient preparation and positioning. This could be attributed to insufficient time spent on instruction and supervision of patient preparation and positioning.

In order to maximize the diagnostic value of every radiograph, the National Radiological Protection Board (United Kingdom)^[7] had proposed a three-point quality scale including excellent, diagnostically acceptable, and unacceptable radiographs. In the present study, 22.4% of the radiographs were of excellent quality and 66.4% were of acceptable quality thereby being of diagnostic value. Nearly 13.2% of the radiographs were of

unacceptable quality. According to the National Radiological Protection Board (United Kingdom),^[7] the basic standard was that the percentage of “unacceptable” radiographs should not exceed 10%. If the current sample was a representative one, then this standard would be a challenge for most operators and a deeper look at the education and training of operators must be done. With this the recommended targets are attainable as in this study, only 13.2% of the radiographs were diagnostically unacceptable, which fell below the results of studies conducted by Dhillon *et al.*^[5] (24.9%), Brezden and Brooks^[1] (18.2%), and Rushton *et al.*^[3] (33%).

CONCLUSION

In conclusion, the value of any diagnostic investigation depends on the proper understanding of the indications and limitations it has. In panoramic radiography, there are numerous operator and patient factors, which can reduce the diagnostic quality of the radiographs. Foremost among these factors is the operator’s understanding of proper patient preparation and positioning factors. The dentist should be aware of the quality of panoramic radiographs, ensuring that they are free of errors. In light of these findings in this study, it seemed that operator understanding of the importance of patient preparation and positioning, better communication with the patient, and spending time in patient positioning could decrease the incidence of these errors and help produce excellent quality diagnostic radiographs.

Financial support and sponsorship

Nil.

Conflicts of interest

There are no conflicts of interest.

REFERENCES

1. Brezden NA, Brooks SL. Evaluation of panoramic dental radiographs taken in private practice. *Oral Surg Oral Med Oral Pathol* 1987;63:617-21.
2. Akesson L, Håkansson J, Rohlin M, Zöger B. An evaluation of image quality for the assessment of the marginal bone level in panoramic radiography. A comparison of radiographs from different dental clinics. *Swed Dent J* 1993;17:9-21.
3. Rushton VE, Horner K, Worthington HV. The quality of panoramic radiographs in a sample of general dental practices. *Br Dent J* 1999;186:630-3.
4. White SC, Pharaoh MJ. *Oral radiology. In: Principles and Interpretation.* 5th ed. Philadelphia: CV Mosby; 2004. p. 200-17.
5. Dhillon M, Raju SM, Verma S, Tomar D, Mohan RS, Lakhanpal M, *et al.* Positioning errors and quality assessment in panoramic radiography. *Imaging Sci Dent* 2012;42:207-12.
6. Khan S, Ashraf B, Mehd H. Evaluation of patient preparation and positioning errors on digital panoramic radiographs. *Pakistan Oral Dental J.* 2015;35:65-9.
7. Hirschmann PN. Guidelines on radiology standards for primary dental care: A resumé. Royal College of Radiologists and the National Radiological Protection Board. *Br Dent J* 1995;178:165-7.
8. Frederiksen NL, Benson BW, Sokolowski TW. Effective dose and risk assessment from film tomography used for dental implant diagnostics. *Dentomaxillofac Radiol* 1994;23:123-7.
9. Pettit GG. “Panoramic radiography,” *Dent Clin North Am* 1971;1:169-82.
10. Horton PS, Sippy FH, Kerber PE, Paule CL. Analysis of interpretations of full-mouth and panoramic surveys. *Oral Surg Oral Med Oral Pathol* 1977;44:468-75.
11. Langland O, Langlais R, Preece J. *Principles of Dental Imaging.* USA: Lippincot Williams Wilkins; 2002.
12. Langlais RP, Langland OE, Nortje CJ. *Diagnostic Imaging of the Jaws.* 1st ed. Baltimore, MD, USA: Williams and Wilkins; 1995.
13. Akarslan ZZ, Erten H, Güngör K, Celik I. Common errors on panoramic radiographs taken in a dental school. *J Contemp Dent Pract* 2003;4:24-34.
14. Al-Faleh W. Common positioning errors in panoramic radiography. *Egyptian Dent J.* 2005;51:1813-17.
15. Schiff T, D’Ambrosio J, Glass BJ, Langlais RP, McDavid WD. Common positioning and technical errors in panoramic radiography. *J Am Dent Assoc* 1986;113:422-6.