



## Case Report

## Single port video-assisted thoracoscopic surgery for removal of a retained bullet in the lung parenchyma; A case report with literature review

Fahmi H. Kakamad<sup>a,b,c,\*</sup>, Razhan K. Ali<sup>d</sup>, Shvan H. Mohammed<sup>c</sup>, Hawar A. Sofi Mohammed<sup>b</sup>, Mohammed Q. Mustafa<sup>c,e</sup>, Abdulwahid M. Salih<sup>b,f</sup>, Bzhwen Y. Abdalla<sup>b</sup><sup>a</sup> Faculty of Medical Sciences, School of Medicine, Department Cardiothoracic and Vascular Surgery, University of Sulaimani, Sulaimani, Kurdistan, Iraq<sup>b</sup> Smart Health Tower, Madam Mitterrand Str, Sulaimani, Kurdistan, Iraq<sup>c</sup> Kscien Organization, Hamid Str, Azadi Mall, Sulaimani, Iraq<sup>d</sup> Shar Hospital, Sulaimani, Iraq<sup>e</sup> Department of Medical Analysis, Tishk International University - Erbil, Kurdistan Region, Iraq<sup>f</sup> Faculty of Medical Sciences, School of Medicine, University of Sulaimani, Sulaimani, Kurdistan, Iraq

## ARTICLE INFO

## Keywords:

Foreign body  
Thoracic injury  
Video-assisted thoracoscopy  
Thoracotomy

## ABSTRACT

**Introduction and importance:** For many years, thoracotomy has been considered as the standard approach for thoracic injuries. The aim of the current paper is to report a successful use of video assisted thoracoscopic surgery (VATS) as the first line approach for the removal of a bullet retained deep in the lung parenchymal tissue.**Case presentation:** A 46-year-old male presented with a vague pain in the chest at the site of a penetrating bullet injury 26 years prior. Chest and native chest Computed Tomography scan (CT scan) showed a 22 mm foreign body inside the substance of the left lower lobe in the anterior segment. Decision was made to remove the foreign body using VATS. The surgery was performed through an uni-port. The left lower lobe was explored and the foreign body was found within the anterior segment. It was removed and the defect was sutured using Vicryl 2/0. **Clinical discussion:** Although VATS has been established to be an accurate evaluating technique for direct evaluation of the chest wall, lung parenchyma, mediastinum and diaphragm, along with its effectiveness in successfully treating a variety of conditions, its use in thoracic trauma is still not well defined.**Conclusion:** This report supports the use of VATS as an effective and minimally invasive approach in the removal of foreign bodies in lung parenchyma.

## 1. Introduction

Thoracic trauma is a leading cause of death in individuals up to 40 years of age [1]. For many years, thoracotomy has been considered as the standard approach for thoracic injuries. It is believed that thoracotomy allows the full visualization of the injury, easy extraction of foreign body, bleeding control, and resection of damaged lung parenchyma [2]. Since the rapid development of thoracoscopic surgery, VATS has been suggested as a less invasive procedure than thoracotomy [3]. VATS is considered to be an effective and safe procedure for the diagnosis and treatment of a substantial variety of thoracic diseases with lower surgical related complications [4]. However, its use remains controversial in thoracic trauma. Previous evidence has reported the favorable effect of VATS for the diagnosis and treatment of traumatic diaphragmatic injury and clotted hemothorax in hemodynamically

stable patients [5].

The aim of the current study is to report successful use of VATS as the first line approach for the extraction of a bullet retained deep in the lung parenchymal tissue for more than 2 decades. The report has been arranged in line with SCARE 2020 guidelines with a brief literature review [6].

## 2. Case report

**Patient's information:** A 46-year-old male presented to the outpatient clinic complaining of vague pain in the chest at the site of a penetrating bullet injury 26 years prior. Two decades ago, the patient was the victim of two bullet entrance wounds with no exit wounds. Operation was commenced and only one of the bullets was retrieved at that time. He survived the incident and the operation and was well after

\* Corresponding author. Doctor City, Building 11, Apartment 50, Sulaimani, Iraq.  
E-mail address: [fahmi.hussein@univsul.edu.iq](mailto:fahmi.hussein@univsul.edu.iq) (F.H. Kakamad).

<https://doi.org/10.1016/j.amsu.2021.102977>

Received 30 August 2021; Received in revised form 18 October 2021; Accepted 28 October 2021

Available online 30 October 2021

2049-0801/© 2021 The Authors. Published by Elsevier Ltd on behalf of IJS Publishing Group Ltd. This is an open access article under the CC BY-NC-ND license

(<http://creativecommons.org/licenses/by-nc-nd/4.0/>).

with no symptoms.

The patient had started feeling a vague generalized chest pain over the last few months and wanted the bullet removed. Past medical, surgical, drug, and family history were negative. He was an active smoker with 40 pack-years.

**Clinical examination:** He was conscious, and oriented. Cardiovascular and respiratory examination were unremarkable apart from a 3-cm round old scar at the left lateral chest wall near the sixth rib.

**Diagnostic assessment:** Hematological tests were normal. Chest x-ray and native chest Computed Tomography scan (CT scan) showed a 22 mm foreign body inside the substance of the left lower lobe in the anterior segment (Figs. 1 and 2). Multiple smaller foreign bodies were also seen in the soft tissue of the chest wall around the level of the scapula.

**Therapeutic intervention:** Decision was made to remove the foreign body using VATS. As part of pre-operative assessment, the only thing of note was a mild restrictive lung picture during the pulmonary function testing. The surgery was performed through an uni-port. During the surgery, the port was introduced in the 5th intercostal space, mid-axillary line. The left lower lobe was explored and the foreign body found within the anterior segment. It was removed and the defect was sutured using Vicryl 2/0. A chest tube was left in place.

**Follow up:** The patient had an uneventful post-operative period, and the chest tube was removed and the patient discharged home on the second post-operative day. One month after operation, the patient was seen to be recovering well and the wound was healthy, the symptoms subsided.

### 3. Discussion

Penetrating or blunt thoracic trauma is a significant cause of morbidity and mortality [7]. One-third of victims die at the site of the trauma. About 85% of survivors may be managed conservatively with a chest tube and close observation, and the other 15% may develop complications that may need an invasive (thoracotomy) approach [8]. There is a switch in the management of thoracic trauma in hemodynamically stable patients in terms of more imaging techniques and minimally invasive surgical approach [9]. Although VATS has been established to be an accurate evaluating technique for the direct evaluation of the chest wall, lung parenchyma, mediastinum and diaphragm and the effectiveness of this approach in successfully treating a variety of

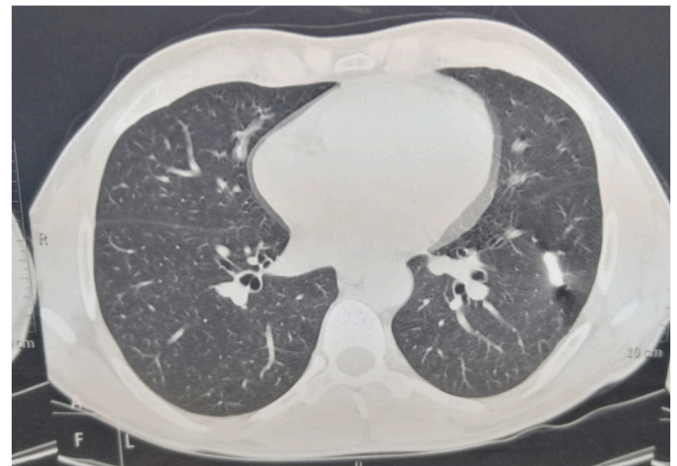


Fig. 2. Native chest computed tomography scan shows bullet shaped metallic foreign body in the anterior segment of the left lower lobe.

conditions, its use in thoracic trauma is still not well defined [2]. Some surgeons shared their successful experiences in the management of patients with penetrating and blunt thoracic injuries [5]. VATS can be applied to the cases where it was found to be a safe and useful and resulted in a better patient's outcome and postoperative course [7]. Other advantages of VATS include lower risk of complications, milder postoperative pain, shorter duration of the chest tube, shorter duration of hospitalization, early and safe return to work, and cost-effective [10]. Retained hemothorax, persistent pneumothorax and diaphragmatic evaluation following thoracoabdominal injury are among the most common indications of VATS in acute setting [11].

The use of VATS in hemodynamically stable thoracic injuries resulted in an accurate diagnosis and provide the possibility of thoracic intervention. A comparison study demonstrated that the rate of wound and pulmonary complications is lower in patients undergoing VATS [9]. The length of incision, amount of bleeding, amount of transfusion, and duration of operation are smaller or shorter in VATS [12]. However, thoracotomy is more effective than VATS in identifying the exact location of the foreign body, and the shorter duration of exploration in the thoracic cavity as well as iatrogenic injuries can be minimized [13].

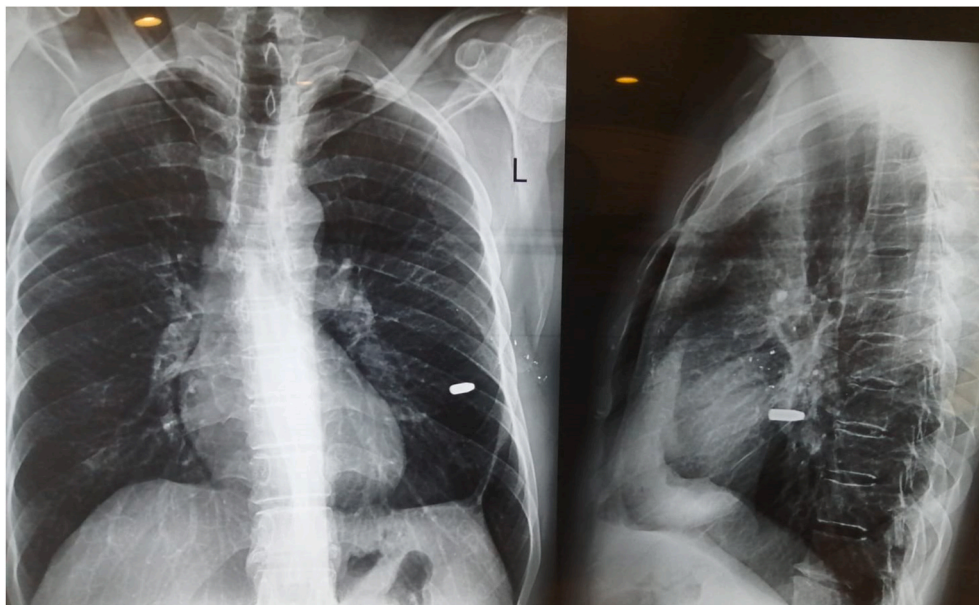


Fig. 1. Plain chest x-ray (PA and lateral view) shows metallic foreign body in the left lower zone.

The use of VATS in removing intrathoracic foreign body is strikingly limited in literature [11]. VATS can be successfully used for the extraction of various form of foreign bodies such as wires, catheter, needle, glass, nails, and bullets [14]. Some studies reported the benefit of VATS in the removal of a Kirschner wire, bullet, and a grenade fragment within the pleural cavity, a bullet located in the pericardial sac, glass fragments and a sharp object in the pleural cavity [5,15]. Retained metallic foreign bodies typically don't need to be removed in asymptomatic patients. Most surgeons recommended not to remove as they become surrounded by fibrous tissue and become non dangerous over time [16]. The decision should be based on comparing the risk of allowing the foreign body to remain inside the chest versus the risks associated with trying to remove it [14]. The current case presented with chest pain due to a retained bullet in the lung parenchyma for approximately 26 years. However, it is believed that the practicality of VATS as compared with thoracotomy shouldn't be used as a principal approach in the removal intrathoracic bullets [14,17].

There are many absolute and relative contraindications for VATS. The major absolute ones are hemodynamic instability, inability to undergo lateral decubitus positioning, inability to undergo single-lung ventilation, and clear indication for thoracotomy, laparotomy or sternotomy [8]. The reported rate of conversion to thoracotomy in thoracic injuries is ranging from 13.8% to 31% [2].

In conclusion, VATS is an accurate and effective technique in the evaluation and treatment of hemodynamically stable chest injuries. This study supported the use of VATS as an effective and safe minimally invasive surgical approach in the removal of foreign bodies in parenchymal lung tissue.

#### Ethical approval

Approval is not necessary for case report in our locality.

#### Source of funding

None is found.

#### Author contribution

Fahmi H. Kakamad, Razhan K. Ali, Bzhwen Y. Abdalla, Hawar A. Sofi Mohammed: surgeons and anaesthesiologist managing the case, follow up the patient, writing the manuscript and final approval of the manuscript. Shvan H. Mohammed, Mohammed Q. Mustafa, Abdulwahid M. Salih: literature review, writing the manuscript, final approval of the manuscript.

#### Consent

Consent has been taken from the patient and the family of the patient.

#### Registration of research studies

According to the previous recommendation, registration is not required for case report.

#### Guarantor

Fahmi Hussein Kakamad is the Guarantor of submission.

#### Patient consent

Written informed consent was obtained from the patient for publication of this case report and accompanying images. A copy of the written consent is available for review by the Editor-in-Chief of this journal on request.

#### Provenance and peer review

Not commissioned, externally peer-reviewed.

#### Declaration of competing interest

None to be declared.

#### References

- [1] Aram Baram, H. Fahmi, Kakamad. Bilateral thoracic trauma; presentation and management, a case series, *Ann. Med. Surg.* 43 (2019) 25–28.
- [2] A.V. Manlulu, T.W. Lee, K.H. Thung, R. Wong, A.P. Yim, Current indications and results of VATS in the evaluation and management of hemodynamically stable thoracic injuries, *Eur. J. Cardio. Thorac. Surg.* 25 (6) (2004) 1048–1053.
- [3] U.Z. Stammberger, C. Steinacher, S. Hillinger, R.A. Schmid, T. Kinsbergen, W. Weder, Early and long-term complaints following video-assisted thoracoscopic surgery: evaluation in 173 patients, *Eur. J. Cardio. Thorac. Surg.* 18 (1) (2000) 7–11.
- [4] A. Imperatori, N. Rotolo, M. Gatti, E. Nardecchia, L. De Monte, V. Conti, et al., Peri-operative complications of video-assisted thoracoscopic surgery (VATS), *Int. J. Surg.* 6 (2008) S78–81.
- [5] L. Lang-Lazdunski, J. Mouroux, F. Pons, G. Grosdidier, E. Martinod, D. Elkaim, et al., Role of video thoracoscopy in chest trauma, *Ann. Thorac. Surg.* 63 (2) (1997) 327–333.
- [6] R.A. Agha, T. Franchi, C. Sohrabi, G. Mathew, A. Kerwan, A. Thoma, et al., The SCARE 2020 guideline: updating consensus surgical Case Report (SCARE) guidelines, *Int. J. Surg.* 84 (2020) 226–230.
- [7] R. Dutta, A. Kumar, C.J. Das, T. Jindal, Emergency video-assisted thoracoscopic foreign body removal and decortication of lung after chest trauma, *General Thoracic Cardiovascular Surg.* 58 (2010) 155–158, 3.
- [8] S.R. Casós, J.D. Richardson, Role of thoracoscopy in acute management of chest injury, *Curr. Opin. Crit. Care* 12 (6) (2006) 584–589.
- [9] Y. Aljehani, E. Alsafwani, N. Alayyaf, A novel approach in retrieving retained pulmonary bullet injury, *Trauma Case Rep.* 21 (2019) 100191.
- [10] M.E. Dörterler, M. Cakmak, T. Günendi, O.H. Kocaman, M.E. Boleken, Use of video-assisted thoracoscopy surgery in the removal of an intrathoracic bullet: a case report, *Int. J. Crit. Illness Inj. Sci.* 10 (4) (2020) 213.
- [11] C.G. Williams, E.R. Haut, H. Ouyang, T.S. Riall, M. Makary, D.T. Efron, et al., Video-assisted thoracic surgery removal of foreign bodies after penetrating chest trauma, *J. Am. Coll. Surg.* 202 (5) (2006) 848–852.
- [12] N. Wu, L. Wu, C. Qiu, Z. Yu, Y. Xiang, M. Wang, et al., A comparison of video-assisted thoracoscopic surgery with open thoracotomy for the management of chest trauma: a systematic review and meta-analysis, *World J. Surg.* 39 (4) (2015) 940–952.
- [13] B.H. Edil, A.L. Trachte, C. Knott-Craig, R.M. Albrecht, Video-assisted thoracoscopic retrieval of an intrapleural foreign body after penetrating chest trauma, *J. Trauma Acute Care Surg.* 63 (1) (2007) E5–6.
- [14] V. Borgaonkar, V. Borgaonkar, Thoracoscopic retrieval of intra-parenchymal foreign body of lung, *Indian J. Surg.* 72 (3) (2010) 252–254.
- [15] J.P. Bartek, A. Grasz, S.R. Hazelrigg, Thoracoscopic retrieval of foreign bodies after penetrating chest trauma, *Ann. Thorac. Surg.* 63 (6) (1997) 1783–1785.
- [16] M. Khalifa, F.M. Abu-Zidan, N. Khan, E. Black, Removal of cardiothoracic war-related shrapnel using video-assisted thoracoscopic surgery, *Ulus Travma Acil Cerrahi Derg* 23 (4) (2017) 348–350.
- [17] K. Potaris, P. Mihos, I. Gakidis, Role of video-assisted thoracic surgery in the evaluation and management of thoracic injuries, *Interact. Cardiovasc. Thorac. Surg.* 4 (4) (2005) 292–294.